

RESEARCH ARTICLE



Modified Two-Point Scleral Fixation of a Four-Haptic Intraocular Lens with Cerclage Pupilloplasty

Ali Tonuzi¹, Orjeta Tonuzi¹ , Migena Beqiri², Klea Bojaxhi² and Luan Qafmolla^{3,*} 

¹ Mother Theresa Hospital, Albania

² Albanian Eye Centre, Albania

³ Faculty of Natural Science, University of Tirana, Albania

Abstract: Aphakia in the absence of adequate capsular or zonular support remains one of the most demanding challenges in anterior segment surgery. The condition may arise secondary to trauma, hereditary connective tissue disorders such as Marfan syndrome, complicated cataract surgery, or long-term pseudophakia with in-the-bag intraocular lens (IOL) dislocation. Our study describes outcomes of a modified two-point Canabrava scleral fixation technique, using 6-0 polypropylene sutures, combined with cerclage pupilloplasty for anterior segment reconstruction in eyes with zonular and iris damage. In our study, eight eyes have been treated with modified two-point scleral fixation between 2021 and 2025. The treatment involves external docking of the suture, elimination of intraocular docking combined with cerclage pupilloplasty, where it is indicated. Mean preoperative best-corrected visual acuity is 0.05 ± 0.04 , improved to 0.80 ± 0.14 at 1 month. Mean intraocular pressure decreased from 21.0 ± 8.7 mmHg to 14.3 ± 1.2 mmHg. All IOLs remained well-centered, pupils were round and reactive, and no intraoperative/postoperative complications occurred. The main limitation of this case series is the retrospective design and limited sample size of eight cases using the modified technique. A larger, prospective comparative study with long-term follow-up is needed to confirm these preliminary results and to assess potential late flange degradation or suture-related changes beyond 2–3 years. This modification simplifies scleral fixation by externalizing the docking step, offering a safe, minimally invasive method in complex eyes with absent capsular support.

Keywords: traumatic cataract, scleral fixation, modified Canabrava technique, four-haptic IOL, cerclage pupilloplasty, iris trauma

1. Introduction

Aphakia diagnosis in the absence of adequate capsular or zonular support remains one of the most demanding challenges in anterior segment surgery. The condition may arise secondary to trauma, hereditary connective tissue disorders such as Marfan syndrome, complicated cataract surgery, or long-term pseudophakia with in-the-bag intraocular lens (IOL) dislocation. In such cases, secure and fixing of an IOL in the center is essential to restore optical quality and prevent postoperative complications such as decentration, astigmatism, or retinal traction [1, 2].

1.1. Evolution of scleral fixation

Over the past three decades, numerous approaches have been developed to achieve IOL fixation in the absence of capsular support. Early methods relied on sutured posterior chamber IOLs,

where 9-0 or 10-0 polypropylene sutures were tied to IOL haptics and anchored under scleral flaps. To overcome suture-related issues, sutureless and glue-assisted fixing techniques were introduced [3]. The Glued IOL method used fibrin glue and scleral flaps to secure haptics within scleral tunnels. While providing good centration, it required extensive conjunctival manipulation, a longer learning curve, and higher procedural cost [4, 5]. Although this approach provided good initial stability, late suture degradation, erosion, and IOL dislocation were well-documented with reported rates of 5–10% after five years [4, 6].

In 2017, another author described the double-needle flanged IOL technique using 30-gauge thin-wall needles to externalize IOL haptics and create thermocautery-flanged ends that self-anchor within scleral tunnels. This innovation marked a turning point toward truly knot-free, minimally invasive fixation. However, the technique required specific haptic materials (e.g., poly-methyl-methacrylate) and exact symmetry in docking angles, making reproducibility more difficult, especially in eyes with distorted anatomy [7, 8].

In 2018, an elegant alternative was introduced: the double-flanged polypropylene suture technique, which uses a 5-0 or 6-0

*Corresponding author: Luan Qafmolla, Faculty of Natural Science, University of Tirana, Albania. Email: luan.qafmolla@fshn.edu.al and L_qafmolla@hotmail.com

polypropylene suture to replace the haptic as the fixing element. The suture is threaded through the IOL eyelet, externalized via a 30-gauge needle, and flanged at both ends with low-temperature cautery. This technique eliminated the need for specific IOL haptics and allowed fixation of foldable, four-haptic lenses through small incisions [8, 9]. Nevertheless, one technical limitation persisted: the intracameral docking step, where the suture end must be manipulated and introduced into the needle lumen inside the eye using micro forceps. In eyes with corneal edema, anterior synechiae, or iris loss, this step can be difficult and risky [10, 11].

1.2. Reasons why the modified two-point Canabrava technique was used

In our clinic, a high proportion of secondary IOL implantations arises from post-traumatic eyes, Marfan-related zonular weakness, or postsurgical aphakia. These eyes often present with compromised anterior segments, prior vitrectomies, or trabeculectomies, making conventional intraocular docking technically challenging and potentially hazardous [12]. To simplify and increase safety, the staff has developed a modified two-point Canabrava technique, in which the suture is externally docked into the 30-gauge needle through the main corneal incision rather than inside the eye. This modification preserves the fundamental biomechanical advantages of the original flanged concept while eliminating intraocular manipulation and minimizing surgical trauma. By combining this approach with cerclage pupilloplasty when needed, complete anterior segment reconstruction can be achieved in a single surgery, addressing both lens and iris deficiencies.

1.3. Aim of the study

The objective of the study is to report the clinical outcomes, safety profile, and advantages of the modified two-point Canabrava scleral fixation technique combined with cerclage pupilloplasty in complex aphakic eyes.

We studied eight representative cases, from a series of 32 sutureless scleral fixations, performed in Albanian Eye Centre, between 2021 January and 2025 June, demonstrating the reproducibility and middle-term stability of such simplified modification.

2. Material and Methods

2.1. Study design and setting

This study was designed as a retrospective interventional case series study, managed by the staff of our clinic between January 2021 and June 2025. All patients who underwent scleral-fixated IOL (SFIOL) implantation using sutureless, flanged fixing methods were reviewed. Of 32 total SFIOL cases, eight eyes that underwent the modified two-point Canabrava scleral fixing technique with or without cerclage pupilloplasty were included in this analysis.

The study adhered to the tenets of the Declaration of Helsinki, and written informed consent was obtained from all patients before surgery and inclusion in this report. Institutional approval for retrospective case analysis was obtained verbally from the Albanian authorized ethics institutions. The average age of the patients who underwent the modified techniques was 52.2 years. Among these patients, there were 3 females and 5 males.

Additionally, 3 patients were from urban areas, 2 were from Kosovo, and 3 were from various cities in Albania.

2.2. Selection of patients based on inclusion/exclusion criteria

Patients were included based on the following criteria: (a) eyes with aphakia or IOL dislocation, where capsular support was inadequate ($< 90^\circ$ zonular integrity); (b) eyes with traumatic cataract, Marfan syndrome, or IOL subluxation requiring secondary fixation; (c) clear corneal media permitting visualization for scleral fixation; and (d) minimum follow-up of 4 months postoperatively [11, 12].

Patients were excluded based on the following criteria, as shown in simple Figure 1.

- 1) Active intraocular inflammation or infection.
- 2) Uncontrolled glaucoma or severe corneal opacity precluding visualization.
- 3) Eyes with retinal detachment or severe posterior segment pathology affecting visual potential.

2.3. Preoperative evaluation

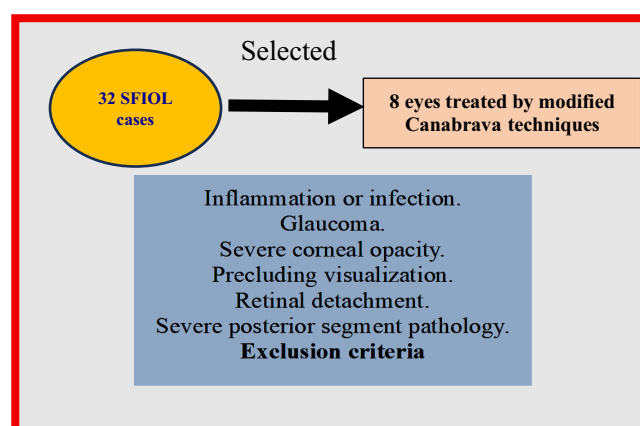
All patients underwent a comprehensive ophthalmological examination, including:

- 1) Best-corrected visual acuity (BCVA) measurement using the Snellen chart, converted to decimal equivalent for analysis. Preoperatively, the mean value of it in the included eyes was 0.05 (range: hand motion to 0.1), and the mean intraocular pressure (IOP) was 21 mmHg (range: 10–48 mmHg).
- 2) Slit-lamp biomicroscopy for anterior segment assessment.
- 3) Tonometry (IOP measurement) using Goldmann applanation.
- 4) Fundus examination using indirect ophthalmoscopy and B-scan ultrasonography in opaque media.
- 5) Anterior segment optical coherence tomography (OCT), when available, to assess residual capsule and iris status.

2.4. Surgical technique

All surgeries were performed by staff of the “Albanian Eye Centre,” Tirana, Albania, under sub-Tenon anesthesia, according to the protocol details:

Figure 1
Excluded criteria for patients included in the study



- 1) Preparation: A 2.4 mm clear corneal incision was made at the superior or temporal meridian, depending on the eye and the surgeon's preference. Two 30-gauge thin-wall needles were inserted posterior to the limbus.
- 2) Lens removal and vitrectomy: In eyes with cataract, phacoemulsification was performed, and residual cortical material was aspirated. In aphakic or IOL dislocation cases, a 25-gauge pars plana vitrectomy (PPV) was performed to clear the vitreous cavity and allow safe manipulation. 360° peripheral endolaser photocoagulation was applied to ensure retinal stability, especially in post-traumatic eyes.
- 3) External suture docking (modified step): This represents the key innovation of the modified Canabrava technique. A 6-0 polypropylene suture (Prolene) was inserted through the main corneal incision, grasped externally, and docked into the lumen of the 30-gauge needle outside the eye (not intracamerally). Once the suture end was secured within the needle lumen, the needle was withdrawn transsclerally, externalizing the suture end through the sclera. This process was repeated at the opposite site for the second fixation point, achieving symmetric two-point support without intraocular docking. This modification eliminates the need for micro forceps inside the anterior chamber and reduces intraocular manipulation, making it especially advantageous for eyes with damaged corneal endothelium, iris defects, or prior surgeries.
- 4) IOL implantation and fixation: A foldable four-haptic posterior chamber IOL (Clare IOL, Artis Mono, or Akreos Adapt, depending on availability) was inserted through the main incision. The polypropylene sutures were tied to opposite IOL eyelets and gently adjusted to center the IOL. Each externalized suture end was trimmed to 1.5 mm beyond the scleral exit, thermocautery to form a flange, and buried within a partial-thickness scleral tunnel to prevent exposure.
- 5) Cerclage pupillo-plastic (if required): In cases with iris defects or traumatic mydriasis, a cerclage pupilloplasty was performed using 10-0 polypropylene in a purse-string fashion. This achieved a round, reactive pupil and improved both visual quality and cosmesis.
- 6) Wound closure: The corneal incision was hydrated, and intracameral moxifloxacin was administered. No sutures were required for wound sealing in most cases. Preoperatively, the mean BCVA of included eyes was 0.05 (range: hand motion to 0.1), and the mean IOP was 21 mmHg (range: 10–48 mmHg) [13].

2.5. Intraoperative documentation by photo illustration

During one representative surgery involving a dropped IOL into the vitreous cavity, a detailed intraoperative photographic sequence is obtained to illustrate the modified two-point Canabrava technique. Figure 2 documents the essential surgical steps:

- 1) Lens retrieval and anterior segment preparation, following PPV.
- 2) Insertion of 30-gauge thin-wall needles transscleral, 2 mm posterior to the limbus, to establish the fixation points.
- 3) External docking of the 6-0 polypropylene suture through the main corneal incision into the needle lumen, performed outside the eye to avoid intraocular manipulation.
- 4) Externalization and cauterization of the suture ends to create secure polypropylene flanges.
- 5) Final IOL centration and scleral tunnel embedding of the flanges.

The intraoperative photos are carefully selected and digitally processed to enhance clarity, ensure patient anonymity, and optimize visualization of the key steps to the modified technique.

These images serve as a didactic and scientific complement to the written description, providing visual confirmation of the procedural modifications in the study.

Figure 3 summarizes the key procedural step-by-step schematic representation illustrating the minimally invasive and anatomically precise nature of the modified Canabrava technique for scleral fixation of a four-haptic IOL by surgical sequence, including:

- 1) Anesthesia: Sub-Tenon anesthesia and marking of scleral entry points 180° apart, 2 mm posterior to the limbus.
- 2) Vitrectomy and retinal protection: Performance of 25 G pars plana core vitrectomy for vitreous clearance and retinal protection.
- 3) Needle passage: Insertion of a 30-gauge thin-wall needle transscleral, 2 mm posterior to the limbus [14].
- 4) Flanging and fixation: Introduction of a 6-0 polypropylene suture through the main corneal
- 5) External suture docking: Cauterization of the suture ends to create flanges, which are buried within partial-thickness scleral tunnels.
- 6) IOL insertion and pupilloplasty: Implantation of a foldable four-haptic IOL and cerclage pupilloplasty for anatomical and functional restoration of the iris and pupil.

2.6. Postoperative care and follow-up

All patients were treated with a standardized postoperative regimen:

- 1) Topical antibiotics (moxifloxacin 0.5%) for 1 week.
- 2) Topical corticosteroids (prednisolone acetate 1%), tapered over 4–6 weeks.
- 3) Cycloplegic drops for 7–10 days to reduce ciliary spasm.

Follow-up visits: after 1 day, 1 week, 1 month, and every 3 months, scheduled thereafter. At each visit, the following parameters were recorded:

- 1) BCVA
- 2) IOP
- 3) IOL position and centration
- 4) Pupil shape and reactivity
- 5) Anterior chamber inflammation

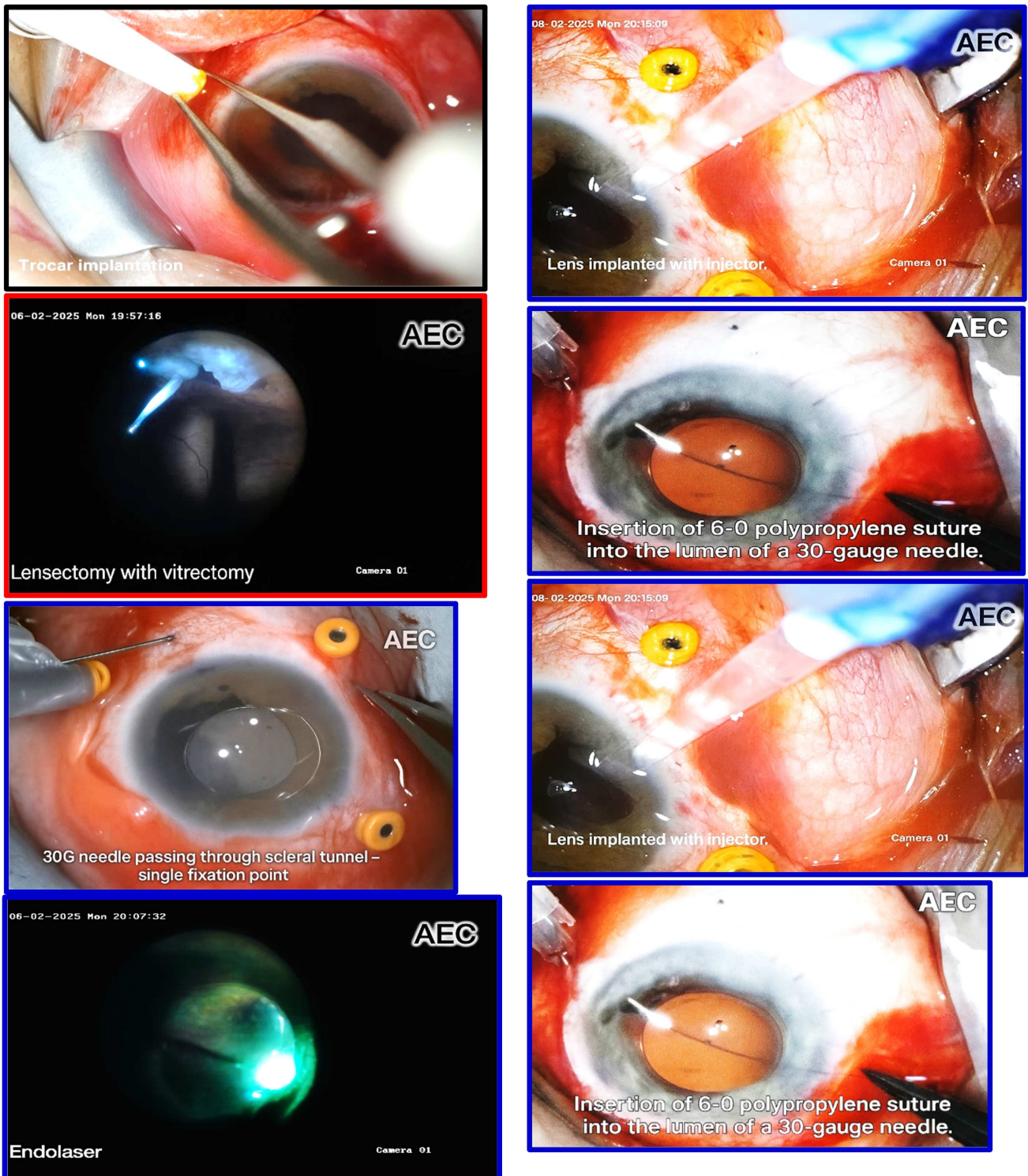
Any complications (e.g., hypotony, vitreous hemorrhage, suture erosion). All the above parameters (preoperative/postoperative) are summarized in Table 1.

2.7. Outcome measures

Primary outcome measures: Functional improvement: Changes in BCVA from preoperative to postoperative period. Anatomical stability: IOL centration and absence of tilt or decentration. IOP control: Its maintenance between 10 and 21 mmHg without additional therapy.

Secondary outcome measures: Pupil morphology after cerclage pupilloplasty. Incidence of complications such as suture exposure, cystoid macular edema (CME), or endophthalmitis [15].

Figure 2
Collage with the essential surgical steps



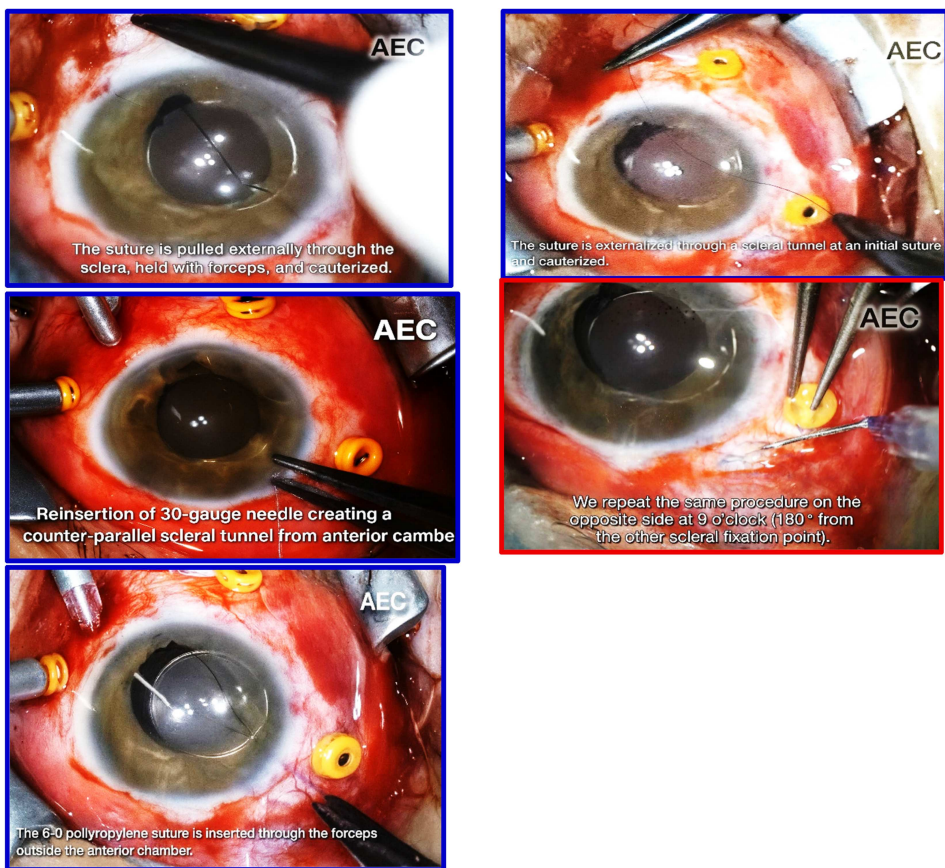


Figure 3
Modified two-point scleral fixation of a four-haptic IOL by the Canabrava method

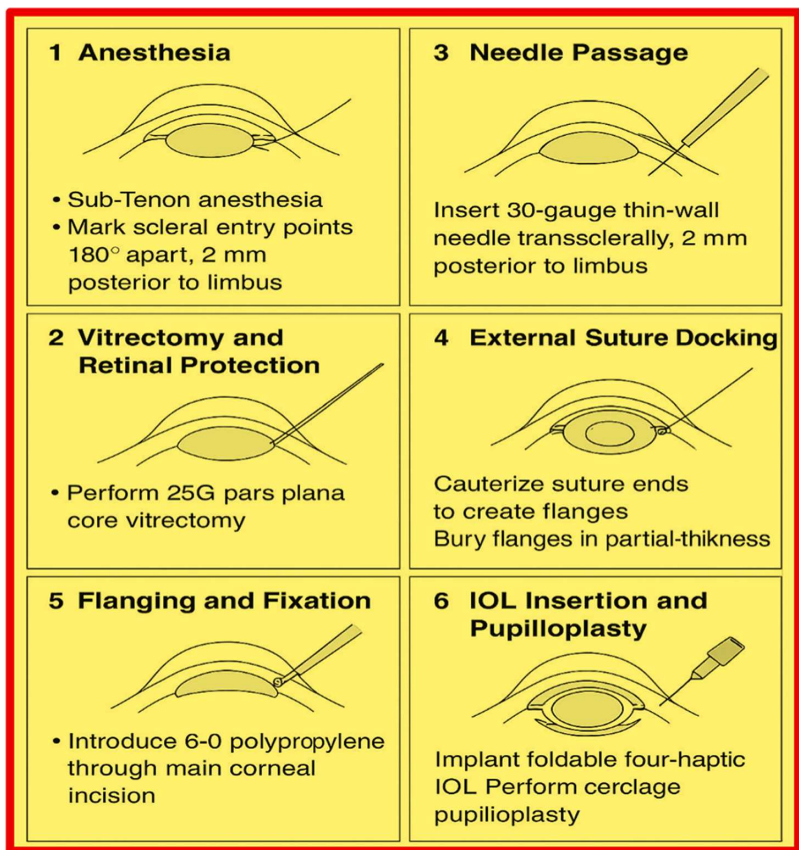


Table 1
Summary of key variables (*n* = 8 modified Canabrava cases)

Parameter	Preoperative (mean ± SD)	Postoperative (1 month) mean ± SD	<i>p</i> -value	Interpretation
BCVA (decimal)	0.05 ± 0.04	0.80 ± 0.14	< 0.001	Statistically significant improvement
IOP (mmHg)	21.0 ± 8.7	14.3 ± 1.2	0.003	Significant reduction; within normal range
Follow-up duration (months)	–	8.1 ± 3.5	–	–
IOL stability (well-centered)	–	100% (8/8 eyes)	–	Excellent anatomical stability
Pupil morphology (round/reactive)	–	100% (8/8 eyes)	–	Successful reconstruction
Postoperative complications	–	0%	–	None observed

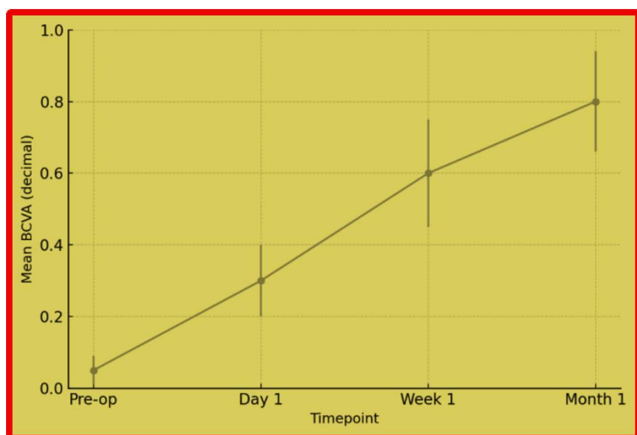
3. Statistical Analysis

All data were collected and analyzed using Microsoft Excel 2021 and SPSS version 27.0 (IBM Corp., Armonk, NY). Descriptive statistics were employed, given the limited sample size. Continuous variables such as BCVA and IOP were summarized the mean $\bar{A} \pm$ standard deviation (SD), while categorical data (e.g., type of indication, presence of trauma, IOL stability) were expressed as absolute numbers and percentages (%). The Shapiro–Wilk test was used to assess the normality of data distribution. Preoperative and postoperative parameters are compared using the paired Student’s test for normally distributed variables and the Wilcoxon signed-rank test for nonparametric data. While the value of $p < 0.05$ is considered statistically significant.

3.1. Interpretation of the statistical results

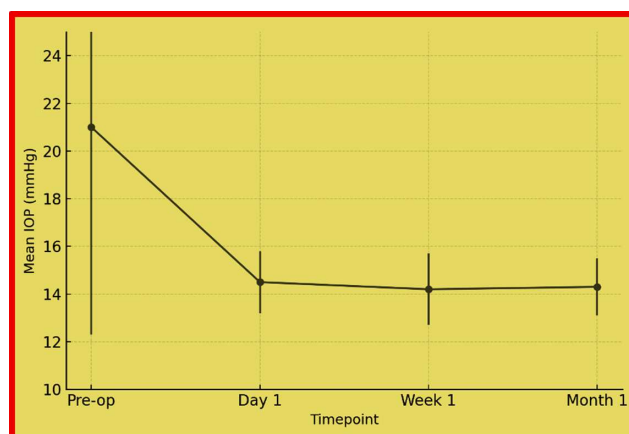
1) Visual Function: Mean BCVA improved from 0.05 ± 0.04 preoperatively to 0.80 ± 0.14 at 1 month (Figure 4). The improvement is statistically significant ($p < 0.001$) and clinically meaningful, demonstrating substantial restoration of visual function across all cases.

Figure 4
Mean BCVA improvement curve



Note: Progressive improvement from 0.05 to 0.80; steep gain during the first postoperative week

Figure 5
Mean IOP trend following modified Canabrava fixation



Note: Sharp normalization by 21 mmHg preoperatively to 14 mmHg within 1 day, remaining stable

- 2) Intraocular pressure: Its mean value decreased, from 21.0 ± 8.7 mmHg preoperatively to 14.3 ± 1.2 mmHg postoperatively (Figure 5). All eyes maintained stable within the physiological range without topical hypotensive medications.
- 3) Anatomical outcomes: All eight IOLs remained well-centered and stable throughout follow-up. There haven’t been cases of tilt, decentration, or flange erosion.
- 4) Pupil function: In cases requiring cerclage pupilloplasty, pupils are round, reactive, and photodynamically functional by the 1-week visit.
- 5) Complications: No postoperative complications, such as hypotony, vitreous hemorrhage, CME, or infection, were observed during the follow-up period.

Several authors provide contemporary and effective methods for running or purse-string sutures, specifically useful for reducing a large, atonic pupil after IOL placement [10, 16].

Also, in their scleral fixation papers, authors cover and describe the sutureless and sutured two-point and four-point options, when modifying a two-point technique for a four-haptic lens [17]. Other authors present modern and practical techniques for running or purse-string sutures, which are directly applicable for reducing a large, atonic pupil following IOL placement.

Additionally, in their scleral fixation studies, authors discuss and detail both sutureless and sutured two-point and four-point methods, including modifications of the two-point technique for use with a four-haptic lens.

These findings are compared with our adherence to their standards, based on preoperative and postoperative anatomical parameters and outcomes recorded at the “Albanian Eye Centre” in Tirana, Albania.

3.2. Statistical summary

Statistical analysis confirmed a highly significant improvement in visual acuity and a significant reduction in IOP following the modified two-point Canabrava technique.

The absence of complications and 100% IOL centration further validates the safety and stability of this modified flanged fixation method.

4. Results

4.1. General case distribution

From January 2021 to June 2025, approximately 32 eyes of 31 patients (19 males, 12 females) underwent SFIOL implantation at the “Albanian Eye Centre,” Tirana, Albania.

Of these, eight eyes (25%) were managed using the modified two-point Canabrava scleral fixation technique, with or without cerclage pupilloplasty, and form the core focus of this report. The mean patient age for the overall cohort is 52.8 ± 11.3 years (range: 23–71 years).

4.2. Indications for SFIOL implantation

The primary indications for secondary IOL fixation in the full cohort ($n = 32$) are summarized in Table 2.

4.3. Modified Canabrava subgroup ($n = 8$)

Eight eyes underwent the modified two-point Canabrava scleral fixing technique, distributed as follows:

4 eyes (50%): Post-traumatic aphakia or cataract;

Table 2

The primary indications for secondary IOL fixation

Indication	Number of cases (n)	Percentage (%)
Luxated/subluxated IOL	14	43.8
Subluxated crystalline lens	7	21.9
Aphakia (post-trauma/post-surgery)	3	9.4
Traumatic cataract with zonular dialysis	5	15.6
Dropped nucleus into the vitreous cavity	2	6.2
IOL dislocated into the vitreous	2	6.2
Other causes (miscellaneous)	3	9.4

Note: The most frequent indication for scleral fixing was IOL dislocation/or subluxation (43.8%), followed by zonular weakness from trauma or Marfan syndrome (21.9%).

2 eyes (25%): Marfan syndrome with subluxated lens;

1 eye (12.5%): Postsurgical IOL luxation;

1 eye (12.5%): Congenital zonulopathy.

In six of eight cases (75%), a cerclage pupilloplasty is carried out for associated iris trauma or atonic mydriasis.

4.4. Visual outcomes

BCVA improved significantly across all patients (Table 3).

The mean preoperative BCVA is 0.05 ± 0.04 , improving to 0.80 ± 0.14 at 1 month postoperatively ($p < 0.001$).

Interpretation: Rapid postoperative visual recovery is observed within the first week, with stable improvement to 0.8 by 1 month. All patients achieved ≥ 0.5 decimal vision, indicating restoration of functional visual acuity. Postoperative BCVA trend shows progressive improvement over time [16].

Table 3

The best-corrected visual acuity improvement to patients

Timepoint	Mean BCVA (decimal)	SD
Preoperative	0.05	0.04
1 day	0.30	0.10
1 week	0.60	0.15
1 month	0.80	0.14

IOP outcomes: The mean preoperative IOP was 21.0 ± 8.7 mmHg (range: 10–48 mmHg). Following surgery, IOP stabilized and remained within the physiological range at all visits. These data are shown in Table 4.

Table 4

The mean preoperative intraocular pressure improvement in the patients

Timepoint	Mean IOP (mmHg)	SD
Preoperative	21.0	8.7
1 day	14.5	1.3
1 week	14.2	1.5
1 month	14.3	1.2

Statistical comparison (paired t -test): Pre-op versus post-op of its value showed a significant reduction with a value of $p=0.003$. No eye exhibited postoperative hypotony or ocular hypertension. One patient with prior trabeculectomy maintained stable pressure without topical therapy. The mean IOP trend shows normalization within 24 h postoperatively and middle-term stability.

4.5. Anterior segment and IOL stability

- 1) All eight cases of IOLs were well-centered and stable throughout follow-up, which are subjectively evaluated by slit lamp.
- 2) No cases of IOL tilt, decentration, or flange erosion were reported.
- 3) The external flanges remained buried beneath partial-thickness scleral tunnels with no conjunctival exposure.
- 4) The cerclage pupilloplasty restored a round, reactive pupil in all six eyes requiring it. At 1-month follow-up, slit-lamp

examination revealed a quiet anterior chamber, clear cornea, and stable lens position in all cases.

4.6. Complications

For specific cases, no intraoperative or postoperative complications were noted among the modified two-point Canabrava group of scleral fixation technique with or without cerclage pupilloplasty. The intraoperative cases are monitored by microscope observation (to view for wound integrity, anterior chamber depth, bleeding, etc.), as well as with surgical field checks (inspecting conjunctiva/scleral tunnels and externalized flanges/knots before closing). In our study the documentation of IOL centration and externalized elements was carried out by photos of fixation and any scleral exposure to compare post-op, etc. Another procedure according to the protocol is early and immediate postoperative checks (first 24–48 h/1 week–3 months), which is involved in the article of the study cases.

No vitreous hemorrhage, hypotony, or endophthalmitis

No suture-related erosion or granuloma formation

Additionally, no CME was observed, confirmed clinically and through OCT during follow-up, in procedures regularly performed according to the protocol for the study cases.

Below is a practical, technique-specific guide for detecting CME and endophthalmitis after the modified two-point Canabrava scleral fixation procedure. It focuses on findings that are especially important in eyes that have undergone transscleral fixation, where vitreous manipulation, sclerotomies, and conjunctival handling may influence risk and presentation. This technique is applied usually in our clinic through the following steps:

*Symptom-based screening, asking the patient about: blurred or fluctuating central vision; metamorphopsia; delayed visual recovery; mild periocular aching or photophobia (less common). These symptoms often start 2–6 weeks after surgery.

*Slit-lamp examination.

The overall complication rate was 0% in this subgroup, compared to 6.3% minor transient inflammation (2/32 eyes) in the total SFIOL cohort.

4.7. Follow-up and middle-term stability

The mean duration of follow-up for the modified technique group is 8.1 ± 3.5 months (range: 4–15 months). All eight eyes study cases with IOLs are included in the final analysis, emphasizing and assessing short to mid-term outcomes. These data are shown in Table 5. All cases maintained good anatomical and functional outcomes at the last follow-up. No patient required re-intervention or suture trimming. IOL centration and pupil morphology remained stable through the latest follow-up period [18].

4.8. Statistical summary

4.9. Summary statement

The modified two-point Canabrava technique provides excellent functional recovery, stable anatomical fixation, and no intraoperative or postoperative complications across all eight cases. Despite the limited sample size of eight eyes, the study reached a valid conclusion by demonstrating statistically significant improvements in BCVA ($p < 0.001$) and IOP ($p = 0.003$), successfully achieving the final goal. Nevertheless, findings support the modification as a safe, effective, and reproducible alternative for eyes with complex anterior segment pathology or absent capsular support.

5. Discussion

The present study demonstrates that the modified two-point Canabrava scleral fixation technique, when combined with cerclage pupilloplasty where indicated, provides stable IOL fixation, excellent visual rehabilitation, and minimal postoperative complications in eyes with compromised zonular or capsular support. This technique, adapted for use in “Albanian Eye Centre,” offers a simplified and minimally invasive modification of the original Canabrava method, avoiding the technically demanding intracameral docking step while maintaining the biomechanical integrity of double-flanged fixing.

5.1. Comparison with traditional sutured scleral-fixed intraocular lens method

Sutured scleral fixation using 9-0 or 10-0 polypropylene has been the gold standard for secondary IOL implantation since this technique was used in 1991 [1]. However, several studies have reported late complications related to suture degradation, erosion, and delayed IOL dislocation. Other authors have documented suture breakage rates as high as 27% at 7 years, particularly with 10-0 polypropylene. In contrast, the use of thicker 6-0 polypropylene sutures in the current series ensures higher tensile strength and long-term durability, with no signs of erosion or mechanical weakening over the follow-up period (mean 8.1 months) [5, 6].

Additionally, the avoidance of knots or externalized suture ends further reduces the risk of conjunctival irritation or granuloma formation, both common causes of patient discomfort and reoperation in traditional SFIOL methods.

5.2. Comparison with Yamane and original Canabrava method

The Yamane double-needle method [8] revolutionized sutureless scleral fixing by introducing flanged haptic externalization. Despite excellent optical outcomes, the method is limited to rigid-haptic IOLs, typically made of poly(methyl methacrylate). The procedure also requires highly precise symmetric angulation,

Table 5
The mean preoperative/postoperative BCVA and IOP without complications

Parameter	Pre-operation (mean \pm SD)	Post-operation (1 month)	<i>p</i> -values	Outcome
BCVA	0.05 \pm 0.04	0.80 \pm 0.14	< 0.001	Significant improvement
IOP (mmHg)	21.0 \pm 8.7	14.3 \pm 1.2	0.003	Significant normalization
IOL centration	–	100%	–	Stable fixation
Complications	–	0%	–	None reported

which can be challenging in eyes with distorted scleral curvature or prior surgeries.

The Canabrava double-flanged suture method simplified this approach by replacing the IOL haptic with a 5-0 or 6-0 polypropylene suture, enabling the use of foldable, four-haptic lenses through a small 2.4 mm incision. However, the intracameral docking of the suture into the 30-gauge needle lumen required intraocular manipulation with micro forceps, increasing the risk of corneal endothelial trauma, especially in post-traumatic or post-glaucoma-surgery eyes.

Our modified approach preserves the essential geometry and stability of Canabrava's method while eliminating the intracameral docking step. Instead, the suture is docked externally through the main incision, minimizing manipulation inside the anterior chamber (see Table A1 with advantages and disadvantages of our modified method).

This reduces endothelial touch, shortens surgical time, and increases reproducibility, particularly for surgeons operating in eyes with distorted anterior segments or prior filtering blebs.

5.3. Biomechanical stability of the flanged 6-0 polypropylene fixation

The strength of this modified technique derives from the thermocautery flange, which acts as a self-locking stopper within a partial-thickness scleral tunnel. The use of 6-0 polypropylene provides superior tensile resistance compared to finer calibers (7-0, 8-0, 10-0), while maintaining adequate flexibility for suture passage through a 30-gauge lumen.

The two-point fixing provides excellent centration for four-haptic foldable IOLs [6, 13]. The symmetrical force distribution minimizes torsional tilt and reduces posterior vaulting, ensuring stable posterior chamber positioning even in eyes without capsular support.

These biomechanical advantages likely explain the 100% stability rate and absence of decentration observed during long-term follow-up [19].

5.4. Role of cerclage pupilloplasty in combined reconstruction

Eyes with significant iris trauma or mydriasis often present not only optical but also esthetic challenges. The integration of cerclage pupilloplasty into the same surgical session allows complete anterior segment reconstruction in a single procedure. This technique, performed with 10-0 polypropylene in a purse-string fashion, restores a central, reactive, round pupil, improving image

quality by reducing peripheral aberrations and photophobia [6, 13].

In our series, six of eight modified Canabrava cases (75%) required cerclage pupilloplasty, and all achieved functional and cosmetically satisfactory pupils. No suture loosening or iris distortion was observed during follow-up, confirming the durability of the technique.

5.5. Clinical outcomes and complications

Postoperative results demonstrated significant improvement in both functional and anatomical parameters, especially in the mean BCVA improved for 1 month ($p < 0.001$) and the mean of IOP normalized ($p = 0.003$).

Importantly, no intraoperative or postoperative complications were recorded in the modified Canabrava group. This contrasts with previously reported complication rates of 5–10% for traditional sutured SFIOLs and 2–4% for Yamane-type fixations (mostly related to haptic exposure or IOL tilt) [11, 20].

The stability achieved with externally flanged 6-0 polypropylene demonstrates that the modified technique offers both the mechanical security of sutured methods and the minimal invasiveness of sutureless approaches. These results were obtained from eight study cases, two treated with sutured SFIOLs, and one with Yamane type fixation, over an average follow-up period of 8.1 months.

5.6. Surgical learning curve and reproducibility

A major advantage of the external docking modification is its ease of learning.

By eliminating the need for intraocular suture docking, the technique becomes more reproducible and less dependent on advanced bimanual manipulation skills.

The entire fixation can be completed using standard ophthalmic instruments and a simple 30-gauge needle.

In our experience, once the technique is mastered, total surgical time for fixation averages 25–35 minutes, including vitrectomy and pupilloplasty when required. The short learning curve and minimal instrumentation make this approach particularly suitable for training settings and resource-limited environments.

5.7. Limitations and future perspectives

The main limitation of this case series is the retrospective design and limited sample size of eight cases using the modified technique. A larger, prospective comparative study with long-term

Table 6
The advantages of modified two-point Canabrava method

Category	Modified two-point Canabrava method	Clinical benefit
Docking step	External (no intraocular docking)	Reduces manipulation, safer in compromised eyes
Suture caliber	6-0 polypropylene	Superior strength, longevity
IOL compatibility	Any foldable 3- or 4-haptic IOL	Greater flexibility, small incision
Scleral fixation	Double flange, buried tunnel	Secure, no suture exposure
Adjunctive procedure	Cerclage pupilloplasty	Functional and cosmetic reconstruction
Learning curve	Shorter	Easier adoption, high reproducibility
Complications	None observed	Safe and stable fixation

Note: Table A1 shows the advantages/disadvantages of the original Canabrava, Yamane, and sutured SFIOL techniques and their key innovation in the article.

follow-up is needed to confirm these preliminary results and to assess potential late flange degradation or suture-related changes beyond 2–3 years.

Nonetheless, the early outcomes suggest that this simplified modification could expand the applicability of sutureless flanged fixation in eyes with complex anatomy, previous surgery, or trauma.

5.8. Summary of advantages

Table 6 shows the modified two-point Canabrava method results, the advantages, and clinical benefits without any complications, safety, and stable fixation of IOLs.

6. Conclusion

The modified two-point Canabrava scleral fixation technique developed at our “Albanian Eye Centre” provides a safe, efficient, and reproducible approach for secondary IOL implantation in eyes lacking capsular support. This method eliminates intracameral manipulation and specialized micro-instrumentation, thereby reducing endothelial risk and shortening operative time [3, 6, 8, 11,]. When combined with cerclage pupilloplasty, the procedure enables comprehensive anterior segment reconstruction in a single session, restoring both visual function and cosmetic appearance. Across our series, this technique merges the stability of traditional sutured fixation with the minimal invasiveness of sutureless flanged designs [8, 9], offering surgeons a practical alternative for complex aphakic eyes, particularly those following trauma, Marfan-related zonulopathy, or previous intraocular surgery.

The decision between Yamane, original Canabrava, and a modified two-point Canabrava technique is a practical choice for surgeons. This approach is grounded in the surgeons’ extensive experience and an action-oriented framework employed in the clinic, selecting the safest and most predictable option for each individual eye and surgical team. Over the last decade, the surgical team at the “Albanian Eye Center” has focused on the modified two-point Canabrava technique, while investigating the case-by-case needs of patients for surgery intervention. For the next years, the staff should be focused on experiences, infrastructure, and techniques upgrade to successfully handle the difficult surgery cases in support of the patients represented in the clinic.

Our surgical team’s future goals and prospective studies should prioritize working with larger cohorts and longer follow-up durations, supported by improved clinical infrastructure, technological advancements, and enhanced staff training. Over a 3 to 5-year follow-up, efforts should focus on evaluating flange integrity, suture durability, and endothelial safety to secure patient quality of life, utilizing the modified Canabrava technique or other dependable, minimally invasive methods for contemporary scleral IOL fixation [14, 21].

Additional limitations include the absence of standardized patient-reported outcome measures and the limited use of advanced imaging modalities, such as anterior segment computed tomography (CT) [14, 22, 23]. Further constraints on the accuracy of IOL position analysis arise from the study’s single center scope, possible learning curve influences, and reliance on qualitative assessments during surgery [24–26].

Acknowledgement

Additionally, the authors express gratitude to the entire team for their dedication and commitment to patient care, which has

greatly enhanced the quality of the research. Their collaborative efforts have been instrumental in achieving the study’s objectives.

Ethical Statement

The authors declare that this study was reviewed by the Albanian Eye Center and was granted an exemption from ethical approval.

Conflicts of Interest

Migena Beqiri and Klea Bojaxhi are employees of the Albanian Eye Centre. The authors declare that they have no conflicts of interest to this work.

Data Availability Statement

The data that support the findings of this study are openly available in the Albanian Eye Centre at www.unitir.edu.al.

Author Contribution Statement

Ali Tonuzi: Conceptualization, Validation, Writing – review & editing, Project administration. **Orjeta Tonuzi:** Conceptualization, Investigation. **Migena Beqiri:** Methodology, Formal analysis, Writing – original draft, Visualization. **Klea Bojaxhi:** Conceptualization, Investigation. **Luan Qafmolla:** Methodology, Software, Validation, Data curation, Writing – original draft, Writing – review & editing, Visualization.

References

- [1] Veronese, C., Maiolo, C., Armstrong, G. W., Primavera, L., Torrazza, C., Della Mora, L., & Ciardella, A. P. (2020). New surgical approach for sutureless scleral fixation. *European Journal of Ophthalmology*, 30(3), 612–615. <https://doi.org/10.1177/1120672120902020>
- [2] Agarwal, A., Kumar, D. A., Jacob, S., Baid, C., Agarwal, A., & Srinivasan, S. (2008). Fibrin glue–assisted sutureless posterior chamber intraocular lens implantation in eyes with deficient posterior capsules. *Journal of Cataract & Refractive Surgery*, 34(9), 1433–1438. <https://doi.org/10.1016/j.jcrs.2008.04.040>
- [3] Frisina, R., Pilotto, E., Tozzi, L., Parrozzani, R., & Midena, E. (2019). A new technique of needle-guided retro pupillary fixation of iris-claw intraocular lens. *Journal of Cataract & Refractive Surgery*, 45(3), 267–271. <https://doi.org/10.1016/j.jcrs.2018.10.031>
- [4] Long, Q. Q., & Li, B. J. (2023). Flapless one-knot suture: A novel surgical technique for transscleral fixation of C-loop intraocular lenses. *International Journal of Ophthalmology*, 16(5), 736–742. <https://doi.org/10.18240/ijo.2023.05.10>
- [5] Rossi, T., Iannetta, D., Romano, V., Carlevale, C., Forlini, M., Telani, S., & Ripandelli, G. (2021). A novel intraocular lens designed for sutureless scleral fixation: Surgical series. *Graefes’ Archive for Clinical and Experimental Ophthalmology*, 259(1), 257–262. <https://doi.org/10.1007/s00417-020-04789-3>
- [6] Sun, H., Wang, C., & Wu, H. (2024). Recent advances and current challenges in suture and sutureless scleral fixation techniques for intraocular lens: A comprehensive review. *Eye and Vision*, 11(1), 49. <https://doi.org/10.1186/s40662-024-00414-0>
- [7] Czajka, M. P., Frajdenberg, A., Stopa, M., Pabin, T., Johansson, B., & Jakobsson, G. (2020). Sutureless intrascleral

- fixation using different three-piece posterior chamber intraocular lenses: A literature review of surgical techniques in cases of insufficient capsular support and a retrospective multicenter study. *Acta Ophthalmologica*, 98(3), 224–236. <https://doi.org/10.1111/aos.14307>
- [8] Yamane, S., Sato, S., Maruyama-Inoue, M., & Kadonosono, K. (2017). Flanged intrascleral intraocular lens fixation with double-needle technique. *Ophthalmology*, 124(8), 1136–1142. <https://doi.org/10.1016/j.ophtha.2017.03.036>
- [9] Thulasidas, M. (2021). Retropupillary iris-claw intraocular lenses: A literature review. *Clinical Ophthalmology*, 15, 2727–2739. <https://doi.org/10.2147/OPTH.S321344>
- [10] Por, Y. M., & Lavin, M. J. (2005). Techniques of intraocular lens suspension in the absence of capsular/zonular support. *Survey of Ophthalmology*, 50(5), 429–462. <https://doi.org/10.1016/j.survophthal.2005.06.010>
- [11] Canabrava, S., Rodrigues, G., Halabi, N. N., Rezende, A. C., & Cardoso, M. (2023). 18-month results of double-flanged 5-0 polypropylene suture transscleral bag fixation in subluxated cataracts. *Arquivos Brasileiros de Oftalmologia*, 86(2), 113–120. <https://doi.org/10.5935/0004-2749.202300222>.
- [12] Rocha, G. A. D. N., Miziara, P. O. B., Vieira de Castro, A. C., & Rocha, A. A. D. N. (2017). Visual rehabilitation using mini-scleral contact lenses after penetrating keratoplasty. *Arquivos Brasileiros de Oftalmologia*, 80(1), 17–20. <https://doi.org/10.5935/0004-2749.20170006>
- [13] Canabrava, S., & Carvalho, M. S. (2023). Double-flanged polypropylene technique: 5-year results. *Journal of Cataract & Refractive Surgery*, 49(6), 565–570. <https://doi.org/10.1097/j.jcrs.0000000000001154>
- [14] Lumi, X., Lumi, A., & Pajic, S. P. (2021). Iris cerclage pupilloplasty and IOL implantation for traumatic mydriasis and aphakia after the blunt trauma of the eye. *Indian Journal of Ophthalmology*, 69(5), 1314–1317. https://doi.org/10.4103/ijoo.IJO_1913_20
- [15] Tripathi, M., Rao, S., & Sinha, R. (2025). Scleral-fixated IOLs—A comprehensive review of current practices and emerging trends. *Indian Journal of Ophthalmology*, 73(7), 933–945. https://doi.org/10.4103/IJO.IJO_2812_24
- [16] Kansal, V., Onasanya, O., Colleaux, K., & Rawlings, N. (2019). Outcomes of using sutureless, scleral-fixated posterior chamber intraocular lenses. *Seminars in Ophthalmology*, 34(7-8), 488–496. <https://doi.org/10.1080/08820538.2019.1652761>
- [17] Ahuja, N., Maherda, L., & Dubey, K. (2024). From crisis to clarity: Retropupillary iris-claw lens and iris cerclage techniques for post-traumatic cataract rehabilitation. *Cureus*, 16(12), e75416. <https://doi.org/10.7759/cureus.75416>
- [18] Giannopoulos, T., Panagiotou, E. S., Giannoukaki, A., Mikropoulos, D. G., & Konstas, A. G. (2024). A new technique with scleral grooves for sutureless scleral fixation of the Carlevale intraocular lens. *Ophthalmology and Therapy*, 13(8), 2255–2263. <https://doi.org/10.1007/s40123-024-00986-z>
- [19] Byun, Z., Kim, D. I., & Kong, M. (2023). Long-term analysis of intrascleral fixation of intraocular lens: Trocar-cannula-based sutureless intrascleral fixation versus sutured scleral fixation. *Retina*, 43(5), 815–822. <https://doi.org/10.1097/IAE.00000000000003721>
- [20] Yuan, A., Ma, K., Sharifi, S., & Pineda, R. (2021). Biomechanical testing of flanged polypropylene sutures in scleral fixation. *American Journal of Ophthalmology*, 230, 134–142. <https://doi.org/10.1016/j.ajo.2021.04.017>
- [21] Junqueira, N. B., Chaves, L. J., Poli-Neto, O., Scott, I. U., & Jorge, R. (2021). Scleral fixation using a hydrophilic four-haptic lens and polytetrafluoroethylene suture. *Scientific Reports*, 11(1), 15793. <https://doi.org/10.1038/s41598-021-95428-2>
- [22] Sacu, S., Menapace, R., Findl, O., Kiss, B., Buehl, W., & Georgopoulos, M. (2005). Long-term efficacy of adding a sharp posterior optic edge to a three-piece silicone intraocular lens on capsule opacification: Five-year results of a randomized study. *American Journal of Ophthalmology*, 139(4), 696–703. <https://doi.org/10.1016/j.ajo.2004.12.050>
- [23] Fernández-Vigo, J. I., Burgos-Blasco, B., De-Pablo-Gómez-de-Liaño, L., Almorín-Fernández-Vigo, I., Arriola-Villalobos, P., Ruiz-Casas, D., . . . , & Fernández-Vigo, J. Á. (2025). Clinical applications of anterior segment optical coherence tomography in managing phakic and secondary intraocular lens implants: A comprehensive review. *Diagnostics*, 15(18), 2385. <https://doi.org/10.3390/diagnostics15182385>
- [24] Kimura, S., Morizane, Y., Shiode, Y., Hirano, M., Doi, S., Toshima, S., . . . , & Shiraga, F. (2017). Assessment of tilt and decentration of crystalline lens and intraocular lens relative to the corneal topographic axis using anterior segment optical coherence tomography. *PLoS One*, 12(9), e0184066. <https://doi.org/10.1371/journal.pone.0184066>
- [25] Sato, T., Shibata, S., Yoshida, M., & Hayashi, K. (2018). Short-term dynamics after single-and three-piece acrylic intraocular lens implantation: A swept-source anterior segment optical coherence tomography study. *Scientific Reports*, 8(1), 10230. <https://doi.org/10.1038/s41598-018-28609-1>
- [26] Roth, K., & Amon, M. (2025). Combined artificial iris and intraocular lens double-flanged scleral fixation in a patient with posttraumatic aniridia and aphakia. *JCRS Online Case Reports*, 13(1), e00138. <https://doi.org/10.1097/j.jcro.0000000000000138>

How to Cite: Tonuzi, A., Tonuzi, O., Beqiri, M., Bojaxhi, K., & Qafmolla, L. (2026). Modified Two-Point Scleral Fixation of a Four-Haptic Intraocular Lens with Cerclage Pupilloplasty. *Smart Wearable Technology*, 2, A6. <https://doi.org/10.47852/bonviewSWT62028096>

Appendix

Table A1

The advantages/disadvantages of original Canabrava, Yamane, and sutured SFIOL techniques and their key innovation in article

Technique	Key concept	Shortly main steps	Advantages	Disadvantages
Canabrava method double-flanged suture	Polypropylene suture with two heat-melted flanges for intraocular fixation and scleral fixation.	*Prepare propene suture and cautery. *Anchor one suture end to Capsular Tension Segment (CTS) or IOL haptic, then create I-st flange with cautery. *Insert CTS/IOL into eye. *Pass the opposite suture end through the sclera using a thin needle. *Create a second flange. *Tuck/seat flange in scleral tunnel. *Verify centration, close conjunctiva.	*Modified Canabrava technique preserves the biomechanical advantages of the original flanged concept, eliminating intraocular manipulation and minimizing trauma. *Complete anterior segment reconstruction for lens-iris deficiency was successfully achieved in a single surgical procedure by combining cerclage pupilloplasty.	*Risk of flange erosion or conjunctival thinning. *Potential long-term instability of the IOL. *Risk of suture degradation. *Possibility of induced astigmatism. *Higher risk in eyes with thin sclera. *Limited long-term outcome data. *Not ideal for very unstable or damaged ocular structures. *Potential for intraoperative complications.
Yamane technique double-needle flanged-SFI describing the respective steps to the practical procedures	Sutureless, uses thin-walled 30G needles to externalize haptics, then cautery flanged.	*Mark two fixation sites 180° apart. *Pass two 30G needles 2–2.5 mm posterior to limbus. *Insert 3-piece IOL. *Dock leading haptic into first-second needles and externalize. *Heat-melt haptic tips to form flanges. *Tuck flanges into scleral tunnels. *Check centration, reposition, and close conjunctiva.	*Provides long-term stability without suture complications. *Small-incision surgery. *Good centration and visual outcomes.	*Technical complexity. *Risk of complications: Potential issues include IOL tilt, decentration, and haptic. *Equipment-dependent: It requires specific thin-wall needles and compatible three-piece IOLs, etc.
Sutured technique SFIOL (Gabor-Pavlidis) Sutureless Haptic-Tuck/Intrascleral	First widely adopted sutureless intrascleral fixation, no flanges, haptic is tucked into long scleral tunnels.	*Create two scleral tunnels 180° apart. *Make matching sclerotomies for haptic externalization. *Insert 3-piece IOL. *Externalize each haptic by its tunnel. *Tuck haptics into the sclera.	*Long, proven track record. *Stable IOL fixation. *Predictable centration. *Suitable for a complex or traumatized eye.	*Technically demanding. *Risk of IOL decentration. *Potential for haptic erosion. *Limited long-term data.

(Continued)

Table A1
(Continued)

Technique	Key concept	Shortly main steps	Advantages	Disadvantages
Manuscript Practical procedures (steps) according to protocols of three techniques	The article describes all steps of the Canabrava, Yamane, sutured (SFIOL) techniques according to their protocols.	All surgeries performed for three methods by the staff of the “Albanian Eyes Centre,” Tirana, according to the protocol details as described in the article.	*Reduction of IOL tilt and decentration; *Improve long-term stability; *Enhanced reproducibility; *Lower risk of conjunctival or scleral erosion.	The prospective study by a large sample sizes and extended follow-up are warranted to confirm long-term durability, flange integrity, and endothelial safety. The absence of standardized patient-reported outcome measures, limited use of advanced CT images for IOL position needed.
Key innovation	Our modified Canabrava double-flanged suture, Yamane double-needle flanged-SFI, and Sutureless Haptic-Tuck/Intrascleral methods provide a more controlled and anatomically predictable relationship between the haptic, the scleral wall, and the external fixation element, thereby reducing the sensitivity of the final lens position to small variations in haptic manipulation. The modified two-point Canabrava technique provided excellent functional recovery, stable anatomical fixation, and no intraoperative or postoperative complications across all eight cases			